Detection of Lesions and Feature Extraction for Diabetic Retinopathy

Anjali.A.Kunghatkar[1], M.S.Panse[2]

Student[1], M.Tech Electronics and Telecommunication, Professor[2]

Department of Electrical Engineering, Veermata Jijabai Technological Institute, Mumbai, Maharashtra, India

***Abstract* – Detection of Diabetic Retinopathy (DR) in early stage is essential to avoid complete blindness. The retinal fundus images of the patients are procured by capturing the fundus of the eye with a digital fundus camera. Fundus Images should be pre-processed to remove the noise, preserve the edges of an image, and enhance the image quality for carrying out further image analysis. This paper provides various pre-processing techniques for detection of DR. The abnormalities in retinal fundus images due to DR are Lesions which includes Microaneurysms, Hemorrhages, exudates and blood vessels. In this study canny's edge detector is used for detection of Lesions and features are extracted.**

***Keywords*- Fundus, Lesions, Canny's edge detector, Median filter.**

I. INTRODUCTION

Diabetic retinopathy is damage to the retina, specifically blood vessels in the retina, caused by complications of diabetes mellitus. Diabetic retinopathy can eventually lead to blindness if left untreated. The retina is light sensitive membrane that covers the back of the eye. If diagnosed and treated early blindness is usually preventable. In diabetic patients due to increase of glucose level in blood there will be rupturing of the small blood vessels called capillaries in the eye. Due to this the blood leaks into the retina of the eye. The abnormal features related to DR which can be found can be microaneurysms, hemorrhages, hard exudates, cotton wool spots etc. The presence of any of the abnormal features helps in classifying the stage of the disease. The first stage of retinopathy is known as Non-Proliferative Retinopathy (NPDR). In NPDR stage, various features like micro-aneurysms, haemorrhages, soft exudates cotton wool spots are present. Depending upon number of these features the classification is performed. Accordingly, Non-proliferative stage can be categorized as Mild, Moderate, and Severe. In PDR stage, new abnormal blood vessels are formed at very high rate. This may result in severe vision loss [1].

II. PROPOSED WORK

In this paper, comparison is carried out between two filters which include Median filter and Gaussian filter and features are extracted.

Collection of Database

Diabetic Retinal image used in the paper is from DIARETDB0 (Standard Diabetic Retinopathy Database Calibration level 0). DIARETDB0 [2] data set contains 130 images and size of [1500x1152] pixels.

A. Pre-processing

The image pre-processing is carried out by various filtering techniques to enhance the image quality, preserves the edges and remove the noise present in the image. The pre-processing produce better quality image which is used for feature extraction for further analysis. The accuracy of DR detection is improved after pre-processing of the image. The image obtained from the database is subjected to the pre-processing steps such as green channel extraction, contrast enhancement, Median filtering and histogram equalization.

1) Green Channel Extraction :

The fundus image is RGB color image. The green channel is the most contrasted one, that the red channel is saturated and that the blue channel does not contain any information [3]. The green channel can give the higher contrast than red and blue. The input fundus image is turned to green channel.

2) Histogram Equalization :

Histogram equalization defined as the process of adjusting intensity values of the image . The aim of histogram equalization used in image processing is to generate an image with equally distributed brightness level over the whole brightness scale [3].

The different filtering techniques which are used for pre-processing are as below:-

3) Median Filter :

The Median filter is a non-linear filter that is mostly used to remove noise in an image. Median filtering is very widely used in digital image processing, it preserves edges while removing noise.

4) Gaussian Filter :

Gaussian filtering is used to blur images and remove noise. The Gaussian function is:

$$G(X,Y) = \frac{1}{2\pi\sigma^2} e^{\frac{X^2+Y^2}{2\sigma^2}}$$

Where σ, indicate the degree of standard deviation.

TABLE I

COMPARISON OF FILTERS

Method	PSNR	MSE
Median Filter	35.02db	15.32db
Gaussian Filter	31.43db	34.78db

B. *Lesions detection*

The abnormalities in retinal fundus images due to DR are lesions which includes Microaneurysms, Hemorrhages, exudates, cotton wool spots etc and blood vessels. Microaneurysms are small swelling that form on the side of the tiny blood vessels and each has a diameter of $\lambda < 125\mu m$ approximately.

Exudates are yellowish or whitish patches of varying size, shapes and location [4]. These are the visible sign of DR and major cause of vision loss.

The extraction of blood vessels is very important in detection of diabetic retinopathy. Optic disc is removed by morphological operation so that the resultant image is without optic disc. Applying canny edge detection algorithm extraction of retinal lesions is done. The results are shown in below fig.2.

C. *Feature Extraction*

To distinguish between the different stages of diabetic retinopathy, various statistical features are extracted. These features are used for classification of DR. Following are various features extracted [5]:

i. Contrast :

It is measure of intensity of a pixels and neighbours over the image. It is calculated as:

$$\sum_{i,j=0}^{N-1} (p_{ij})(i-j)^2$$

ii. Correlation :

It is measure of how correlated a pixel is to its neighbour over the whole image. It is calculated as:

$$\sum_{i=0}^{M-1} \sum_{j=0}^{N-1} \frac{(i-\mu_i)(j-\mu_j)p_{i,j}}{\sigma_i \sigma_j}$$

iii. Homogeneity :

It is a value that measures the closeness of the distribution of an element in grey level co-occurrence matrix to the grey level co-occurrence diagonal. It is calculated as:

$$\sum_{i,j} \frac{p(i,j)}{1+|i-j|}$$

iv. Entropy :

It shows the amount of information of the image that is needed for the image compression. Entropy is calculated as:

$$\sum_{i,j=0}^{N-1} -\ln(p_{ij})p_{ij}$$

v. Area, Perimeter and Count of :

microaneurysms, exudates and blood vessels.

Count *= max (max(l(ROI)));*

Area *= ∑(weights(:),[],'double')/8;*

Perimeter *= ∑ (Tedges, Ledges, Bedges , Redges).*

III. RESULTS

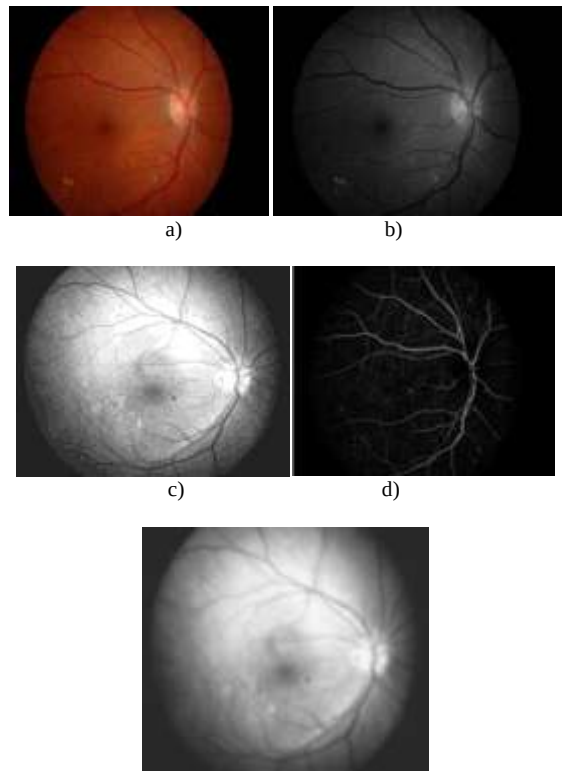

Fig.1. Pre-processing images a) Input image b) Green channel c) Histogram equalization d) Median Filtered image e) Gaussian filtered image.

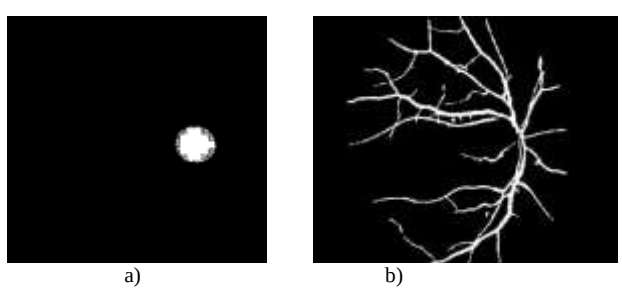



c) d)

Fig.2. Lesions detection a) Optic disc b) Extracted blood vessels c) Extracted Exudates d) Extracted Microaneurysms.

IV. CONCLUSIONS

It is concluded that the Mean Square error is least and Peak signal to noise ratio is maximum in the Median filter. So pre-processing using Median filter provides the better quality of image. The Fundus image is pre-processed to improve the quality of the image, and the lesions of DR are filtered out based on canny's edges detection and morphological operations. The features of the segmented image are extracted. Future work is to feed the extracted features to the SVM classifier that will differentiate between NPDR (Non-Proliferative Retinopathy) and PDR (Proliferative Retinopathy).

REFERENCES

[1] Du, Ning, and Yafen Li. "Automated identification of diabetic retinopathy stages using support vector machine." *Control Conference (CCC), 2013 32nd Chinese*. IEEE, 2013.

[2] Diabetic retinopathy database and evaluation protocol (DIARETDB0). Electronic material (Online). Available online at: http://www.it.lut.fi/project/imageret/files/diaretdb0 [referred 19.2.2010].

[3] Niemeijer, Meindert, et al. "Automatic detection of red lesions in digital color fundus photographs." *IEEE Transactions on medical imaging* 24.5 (2005): 584-592.

[4] Yun, Wong Li, et al. "Identification of different stages of diabetic retinopathy using retinal optical images." *Information sciences* 178.1 (2008): 106-121.

[5] Paing, May Phu, Somsak Choomchuay, and MD Rapeeporn Yodprom. "Detection of lesions and classification of diabetic retinopathy using fundus images." *Biomedical Engineering International Conference (BMEiCON), 2016 9th*. IEEE, 2016.