

Early Mobilization and Cocontraction Exercises in Multiple Communitied BI-Lowerlimb Fractures (Case Report)

Dr. Atul Kale, Dr. Pankaj Raghute, Dr. Amol Shinde, Dr. Kushal Toshniwal, Dr. Neha Deshmukh, Dr. Dipesh Sadhawani

Department of Musculoskeletal Physiotherapy, Niharika College of Physiotherapy, India

DOI: <https://doi.org/10.51584/IJRIAS.2025.100800011>

Received: 17 July 2025; Accepted: 02 August 2025; Published: 29 August 2025

ABSTRACT

Multiple non displaced lower limb fractures of bilateral tibia and fibula are often more complex and involve a disturbance in locomotor function for the individual.

Involvement of articulating surface in such fracture requires skill hand, suitable implants for maximal functional outcome. When the fracture is displaced, unfavourable outcomes can occur and lead to early osteoarthritis of the knee. Additionally, knee pain and stiffness due to immobilization or surgical reduction and stabilization can limit one's overall lower limb functions specifically related to weight-bearing. Rehabilitation following such a fracture is complex & challenging. Early mobilization on the bed with closed kinematic exercises can lead to a better prognosis.

Therefore, this case report aims to present the evaluation and rehabilitation of a 47-year-old female following a comminuted fracture of bilateral tibia and fibula, which is surgically managed with intramedullary nailing, plating, and screw femur. The rehabilitation over a 9 months course was done and the benefits of early mobility in the rehabilitation were emphasized.

INTRODUCTION

Fracture is the most common nonfatal injury in a road traffic accident. (1) Multiple fractures are common in accidental vehicle injury. Nowadays one of the leading causes of disabilities and hospitalization in developing countries is increasing number of limb fractures. Tibial fractures are most common amongst all long-bone fractures. Trauma is one of leading causes for fractures, this kind of injuries need a history of high amount of impactful forces. Healing of such kind of multiple fractures takes a longer duration than the normal healing. Treating the patient with traumatic injuries physical therapist has to deal with various aspects other than physical like psycho social also. Individuals with road traffic accidents deal with mental and physical trauma too. Patient's education plays a crucial role while treating the patient from such background. Get back into day today routine was the main aim of our patient and how much time it will her to achieve that. initial starting movement during healing phases needs good about healing phases. Managing such injuries becomes a challenging task for the health care team. Multiple fractures frequently lead to an unfavourable outcome. Isolated fracture of any bone is easy to manage and usually leads to a good recovery.

NARRATIVE

Presenting Complaints:

Patient Presented with road vehicular accident near kasara on 09/04/2017 at around 05.30 am leading to head injury with poly trauma with bony deformity in both the lower limbs with swelling, restricted movements and restlessness

Past History: No Other Past Significant Medical Record

CNS Examination: Conscious And Oriented, GCS Score =15 Responding And Obeying Commands, Moving

all 4 Limbs

Systemic Examination: All reports attached along with patient file.

Radiological Investigations:

09.04.2017 USG Of The Abdomen And Pelvis : NORMAL:Grade

I fatty liver.7.8x6.2 cm sized intramural fibroid in the posterior wall.

09.04.2017 2D

Echocardiography:

1. Concentric hypertrophy of LV.
2. No regional wall motion abnormality at rest.
3. Normal IV systolic function.
4. Grade I diastolic dysfunction.

Course in Hospital:

The patient was admitted and the treatment started accordingly. Clinical examination and CT scan of brain were done. In view of the same opinion of neurosurgeon and general surgeon was taken, both advised conservative management. Radiological investigations were s/o: 1 Swelling/tenderness with bony deformity and crepitus over bilateral proximal leg s/o bilateral tibia fracture with overlying skin showing deep contusions.

2. Swelling and deformity over the right thigh s/o fracture neck femur
3. Dislocation of the Left ankle joint with exposed medial malleolus and talus with lateral malleolus with deep circumferential degloving injury with restricted movement.
4. Pelvic Tenderness present but bilaterally Pelvic is stable

Surgery: The patient underwent left ankle joint reduction of dislocation and debridement and reconstruction of the ligament under SA on 09/04/2017.

NOTES:

- 1) Wound debridement, irrigation, and lavage of the circumferential degloving injury over the bimalleolar region on with protruding talus and medial distal articular surface and lateral distal articular surface.
2. Reduction of dislocation ankle joint with wound debridement and repair of the external retinaculum and medial Deltoid ligament-second lateral ligament complex calcaneo-fibular dislocation found to be stable.
3. Below knee pop slab given.
4. Small chip fracture fragments of the anterior and lateral process of talus came in place checked under Carmhence internal fixation done.

10/04/2017 close reduction of ankle subtalar joint B/L

11/04/2017 - close reduction with internal fixation with inn for right fractures shaft of femur 18/04/2017-close reduction & internal fixation of B/L fracture Tibial condyle

Diagnosis:

1. B/L tibial proximal 1/3 fracture types 6 with blisters over left side
2. Right side shaft femur proximal 1/3 fracture
3. Right ankle dislocation reduced
4. Left side subtalar subluxation lateral aspect

PastHistory:

Patient is having H/O surgery of right sided clavicle two years back in Jalgaon

OT Notes

- On 10/04/2017—under EA close reduction of B/L ankle joint was performed under anesthesia with A/K-slab-B/L
- On 11-04-2017—under SA+EA

Close reduction and internal fixation with 9mm/380 mm (titanium) for right side fracture femur.

- On 18/04/17— under SA+EA close

Reduction & internal fixation of b/l fracture tibia done. Tibia locking plating (titanium) done. Using mippo technique i.e. Minimal invasive per cutaneous plate osteosynthesis.

- On 71/04/2017 — post open wound dressing done it was dry, no discharge wound is healing

Condition of Patient On Discharge: Patient conscious, co-operative and well oriented with time, place & person.

T- afebrile, P:92/min, BP:130/70, RR:20/min, SpO2: 98%

Perspective

Patient was in a shock and tremendous pain after gaining consciousness post-surgery. Initially she was depressed about her situation, being bedridden feeling she won't come out of that situation. But she was constantly saying "I have to come out of this" She had a positive approach towards her rehabilitation

Discussion

In this case where 47-year female had multiple fractures including comminuted fracture of BL tibia was rehabilitate using closed kinetic exercises on the bed which was started on bed itself before going for weight-bearing position. Early loading on joints with minimal contraction of muscle will condition patients for weight bearing which she needed for standing with supportive devices. performing an open chain exercises during initial stages of fracture healing may not have that great impact as the muscle attachment to that site of fracture can move as the site of attachment which can cause delay in fracture healing. advantage of using close chain exercises over open chain exercises is without disturbing comminuted fracture healing mechanism may get improvement in joint stability, patient confident while performing exercises and healing mechanism get fastened.¹¹ The study also concurred with Menkes et al.'s results who found that bone compression, tension, torsion, or shear was a causative factor of bone overload. The differences in the bone's electrical power produced by such mechanical forces act as an electrical field that promotes cellular activity, causing minerals to be deposited in the area under stress. Restricted weight-bearing and ROM exercise five days in a week with an efficient amount of breathing exercises.

As described above, evidence suggests the potential benefit to fracture healing and patient outcomes when early

mobilization and muscle strengthening are employed during the rehabilitation of patients with lower extremity trauma. In addition, improved mobility also confers more general benefits, such as the reduced risk of muscular atrophy, joint stiffness, venous thrombo embolism (VTE) and pressure ulcers.

In this case decision regarding weight-bearing for walking was a tougher decision as the patient was managed with ORIF stress sharing devices as it works on the mechanism of callus formation and wedon' tha veanidea about material durability. Callus formation what we can seeon Xray was that much reliable so we decided to start with full weight-bearing which supported in the best manner.

After 9 months of aggressive rehabilitation, she is now able to walk and stand for a long duration without support.

CONCLUSION

While treating this case we found that independence for performing her daily living activity keeps great importance. Weight-bearing on the lower limb in comminuted fractures still needs also to research. Inthis case we have emphasized on early mobility and close kinematic chain exercises from which saw the better result on ADL activities & locomotors function of the patient.

Declaration of patient consent

The consent was obtained from the patient as the author has given information regarding his clinical information to be published in the journal The patient know that their personal information is used for the study propose and it will not be disclosed.

Financial support and sponsorship

Nil.

Future scope: effect of co-contraction exercises on healing mechanism with micro cellular changes in skeletal structures

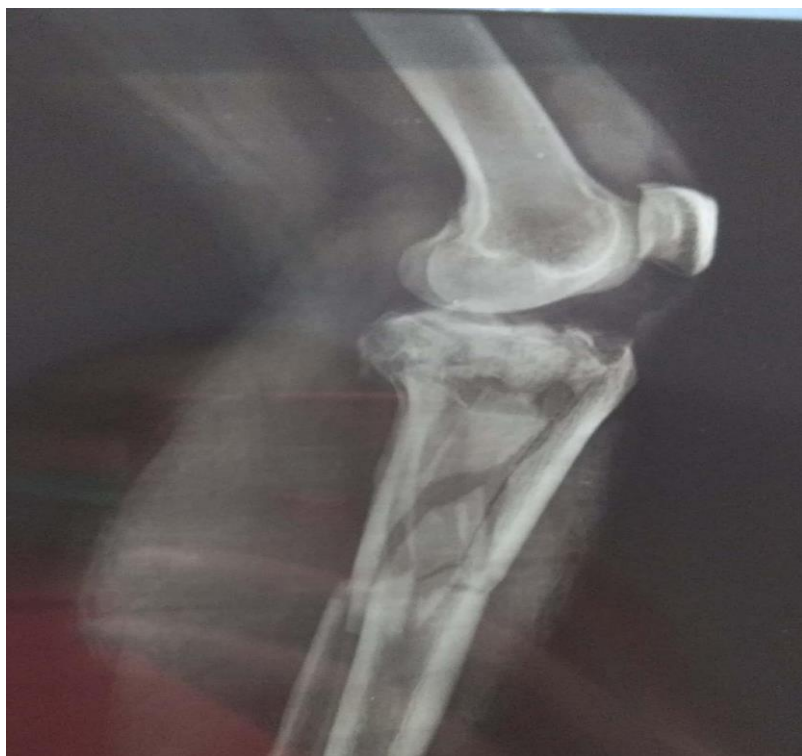REFERENCES

1. Brown PW, Urban JG. Early weight-bearing treatment of open fractures of the tibia. An end-result study of sixty-three cases. *J Bone Joint Surg Am.* 1969;51(1):59-75.
2. Ganveer GB, Tiwari RR. Injury pattern among non-fatal road traffic accident cases: a cross-sectional study in Central India. *Indian J Med Sci.* 2005;59(1):9-12.
3. Singaram S, Naidoo M. The physical impact of long bone fractures on adults in KwaZulu-Natal. *S Afr J Physiother.* 2020;76(1):1393. Published 2020 Aug 20. doi:10.4102/sajp.v76i1.1393
4. Hoyt, B.W., Pavey, G.J., Pasquina, P.F. et al. Rehabilitation of Lower Extremity Trauma: a Review of Principles and Military Perspective on Future Directions. *Curr Trauma Rep* **1**, 50–60 (2015). <https://doi.org/10.1007/s40719-014-0004-5>
5. Hoyt, B.W., Pavey, G.J., Pasquina, P.F. et al. Rehabilitation of Lower Extremity Trauma: a Review of Principles and Military Perspective on Future Directions. *Curr Trauma Rep* **1**, 50–60 (2015). <https://doi.org/10.1007/s40719-014-0004-5>
6. Portier H, Benaitreau D, Pallu S. Does Physical Exercise Always Improve Bone Quality in Rats?. *Life (Basel)*. 2020;10(10): 217. Published 2020 Sep 23. doi:10.3390/life10100217
7. Osipov B, Emami AJ, Christiansen BA. Systemic Bone Loss After Fracture. *Clin Rev Bone Miner Metab.* 2018 Dec;16(4):116-130. doi: 10.1007/s12018-018-9253-0. Epub 2018 Dec 6. PMID: 31363348; PMCID: PMC6667184.
8. Solomon LB, Callary SA, Stevenson AW, McGee MA, Chehade MJ, Howie DW. Weight-bearing-induced displacement and migration over time of fracture fragments following split depression fractures of the lateral tibial plateau: a case series with radiostereometric analysis. *J Bone Joint Surg Br.* 2011 Jun;93(6):817-23. doi:10.1302/0301-620X.93B6.26122. PMID: 21586783.
9. Thabet AAE, Alshehri MA, Helal OF, Refaat B. The impact of closed versus open kinetic chain exercises on osteo


porotic femur neck and risk of fall in postmenopausal women. *J Phys Ther Sci*. 2017 Sep;29(9):1612-1616. doi:10.1589/jpts.29.1612. Epub 2017 Sep 15. PMID:28931999; PMCID:PMC5599832.

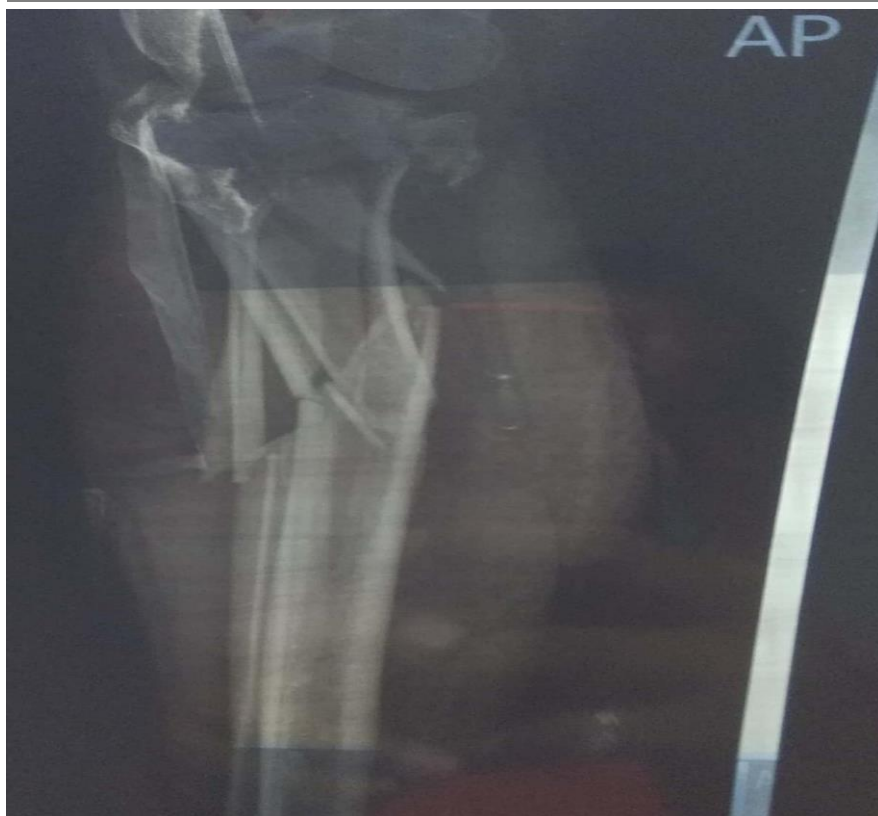10. Patil S, Steklov N, Bugbee WD, Goldberg T, Colwell CW, D'lima DD. Anti-gravity treadmills are effective in reducing knee forces. *J Orthop Res*. 2013;31(5):672–9.
11. Lindgren M, Unosson M, Fredrikson M, Ek A. Immobility—a major risk factor for development of pressure ulcers among adult hospitalized patients: a prospective study. *Scand J Caring Sci*. 2004;18(1):57–64
12. Bigham-Sadegh A, Oryan A. Basic concepts regarding fracture healing and the current options and future directions in managing bone fractures. *Int Wound J*. 2015;12(3):238-247. doi:10.1111/iwj.12231

ATTACHMENTS



Upper end of tibia comminuted fracture





Case Report generated using CARE-writer, care-writer.com

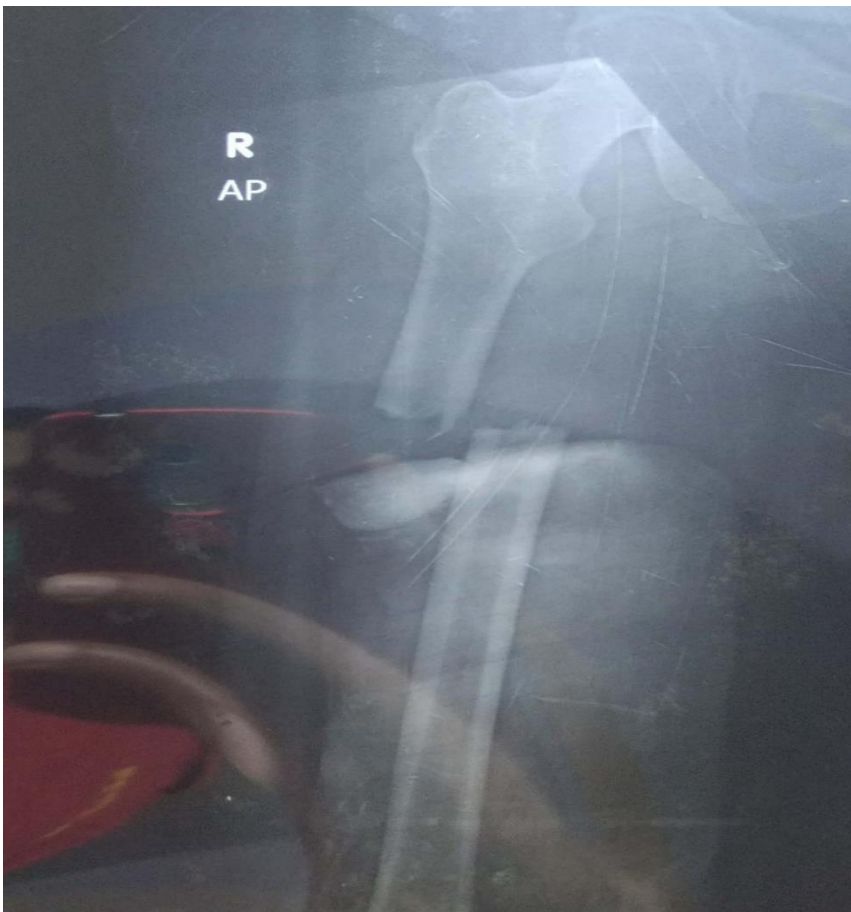Communicated fracture of upper endrttibiallateral view.



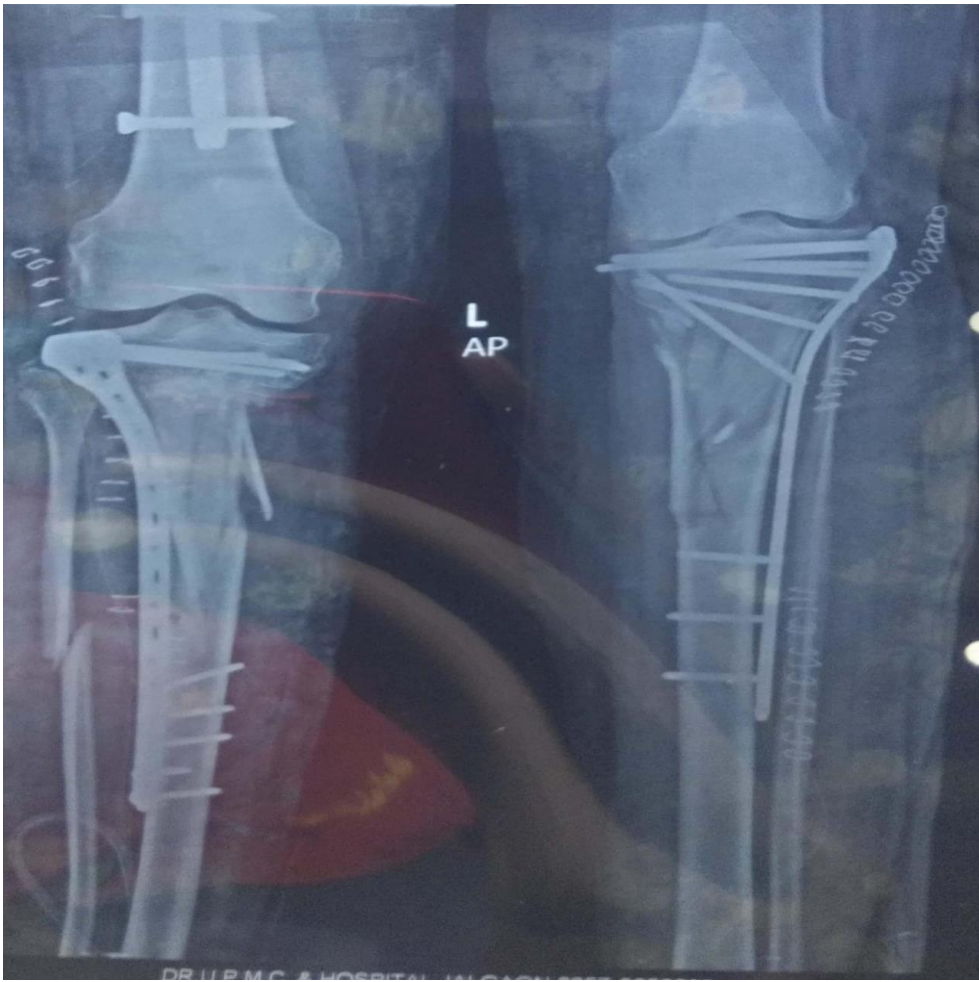Case Report generated using CARE-writer, care-writer.com



Post operative xray after OIRF



RT shaft off emurdis placed fracture



Bilateral OIRF post operative x-ray